

Prospective Clinical Trial of Diagnostic Peritoneal Lavage to Detect Positive Peritoneal Cytology in Patients With Gastric Cancer

JAMES J. MEZHIR, MD, MITCHELL C. POSNER, MD, AND KEVIN K. ROGGIN, MD*

Department of Surgery, University of Chicago Medical Center, Chicago, Illinois

Background and Objectives: Positive peritoneal cytology equates M1 disease in patients with gastric cancer. Diagnostic peritoneal lavage (DPL) is a proven test to detect occult visceral injury in trauma patients. The objective of this study is to determine whether DPL can be used to assess peritoneal cytology in patients with gastric cancer.

Methods: Patients with gastric adenocarcinoma were prospectively enrolled to undergo DPL prior to diagnostic laparoscopy (DL). Saline was instilled through a percutaneous catheter and fluid was collected for cytology (DPL-cyt). Washings obtained during DL were used as controls (DL-cyt).

Results: DPL was successful in 22/27 patients (81.5%). Among the 22 successful DPLs, 12 had positive cytology (54.5%). Positive DPL-cyt specimens matched DL-cyt specimens in 12/12 cases (specificity = 100%). One of 10 cases with negative DPL-cyt was positive on the final DL-cyt (sensitivity = 92%). There were six patients with negative DPL-cyt who had visible M1 disease diagnosed with DL (DPL evaluation of M1 disease, sensitivity 54.5%, specificity = 100%).

Conclusions: DPL is a safe method of detecting positive cytology in patients with gastric cancer, however gross M1 disease may be missed without visual inspection. The specific role of DPL in the staging workup of patients with gastric cancer remains to be determined.

J. Surg. Oncol. 2013;107:794–798. © 2013 Wiley Periodicals, Inc.

KEY WORDS: peritoneal cytology; diagnostic peritoneal lavage; gastric cancer; metastasis

INTRODUCTION

Positive peritoneal cytology is a powerful prognostic factor that has independently been associated with poor long-term survival in patients with gastric cancer following resection [1–4]. Due to the prognostic value of positive peritoneal cytology, it has recently been included in the American Joint Committee on Cancer staging system as M1 disease in gastric cancer patients [5]. The actual rate of positive peritoneal cytology is unknown with published rates ranging from 6.5% to 31%, and may correlate with more advanced T- and N-stage [1,3,4,6]. Furthermore, most prospective trials omit assessments of peritoneal cytology, presumably because of the added cost and inconvenience of the required diagnostic laparoscopy [7,8]. In many centers, peritoneal washings are performed during diagnostic laparoscopy prior to initiation of perioperative chemotherapy for patients with locally advanced disease [3,7]. Due to the low yield of peritoneal cytology in early stage disease, some patients may be excluded from this additional staging modality [9].

Percutaneous diagnostic peritoneal lavage (DPL) was introduced by Root [10] as a procedure to determine the likelihood of peritoneal penetration and injury to the abdominal viscera in trauma patients [11]. In large studies, DPL has been shown to be rapid, safe, and effective in this setting [12]. Typically, 1 L of saline is held above the patient and passively infused into the peritoneal cavity through a percutaneously inserted catheter using the Seldinger technique [12]. Following infusion, the empty bag is left to gravity and the effluent measured for red blood cells and bilirubin to determine the presence of solid organ injury.

Due to the nature of this procedure, this technique could potentially be utilized to obtain peritoneal washings as part of the staging workup of patients with locally advanced gastric cancer. Patients with positive peritoneal cytology on DPL could be spared from a non-curative radical resection and have expedited access to systemic therapies. No studies to date have assessed the value of DPL in

patients with gastric cancer. The objectives of this prospective study are (1) to determine the technical safety and feasibility of DPL in gastric cancer patients and (2) to calculate the sensitivity and specificity of DPL for detecting positive peritoneal cytology.

METHODS

Clinical and pathologic data was collected on all patients including age, gender, tumor site, and clinical and pathologic stage. All patients were staged using the seventh edition of the AJCC staging system [5]. Prior to diagnostic peritoneal lavage (DPL) and diagnostic laparoscopy (DL), patients were evaluated with computed tomography of the chest, abdomen, and pelvis and in most patients, endoscopic ultrasound. This prospective study was approved by the Institutional Review Board at the University of Chicago Medical Center. At our institution, DL is performed as a separate outpatient procedure in patients with locally advanced disease and helps stratify patients for multidisciplinary treatment planning. For the purposes of this study, we also enrolled patients who were undergoing diagnostic

This manuscript was presented at the Society of Surgical Oncology 63rd Annual Cancer Symposium, St. Louis, MO, April 3–7, 2010.

Conflict of interest: none.

James J. Mezhir's present address is University of Iowa Hospitals and Clinics, 200 Hawkins Drive; 4642 JCP, Iowa City, IA 52242.

*Correspondence to: Kevin K. Roggin, MD, Associate Professor of Surgery and Cancer Research, University of Chicago Medical Center, 5841 S. Maryland Avenue, MC 5094, Chicago, IL 60637. Fax: 773-834-4007. E-mail: kroggin@surgery.bsduchicago.edu

Received 10 October 2012; Accepted 29 January 2013

DOI 10.1002/jso.23328

Published online 26 March 2013 in Wiley Online Library (wileyonlinelibrary.com).

laparoscopy to confirm suspicion for M1 disease. High-risk gastric cancer patients (clinical T3, N-positive, M1, or those with <T3, node negative, and high risk pathologic features) undergoing diagnostic laparoscopy as part of their routine staging modality were enrolled in this study following informed consent.

DPL was performed following induction of general anesthesia, placement of an orogastric tube, urinary bladder catheter, and administration of a second generation cephalosporin antibiotic. The technique of percutaneous and open DPL has been previously described [12]. The technique utilized in this study was primarily open DPL using a commercially available kit (Arrow International Peritoneal Lavage Kit (Reading, PA). Briefly, a small infraumbilical incision at the same location planned for DL was made and taken down through the fascia sharply to gain access to the peritoneal cavity (Fig. 1). A 8-French silastic catheter with extra side-holes was then inserted into the peritoneal cavity and a figure-of-eight suture was used to close the fascia prior to the introduction of fluid. One liter of saline is then infused by holding the saline bag above the patient to counter intra-abdominal pressure. Following infusion, the bag is placed on the ground and the effluent collected. Successful DPL was defined as infusion of at least 500 cm³ of fluid and a return collection of at least 200 cm³ of effluent. When sufficient fluid was not obtained, additional fluid was infused. Any effluent collected was defined as DPL-cyt.

Once the DPL was completed, DL was performed in all patients. The DPL incision was extended to insert a 10/12 mm blunt trocar into the peritoneal cavity via direct visualization. One or two 5 mm Applied trocars were inserted into the peritoneal cavity along the subcostal margin at the mid-clavicular line under laparoscopic guidance. The peritoneal cavity and liver surface were carefully examined for evidence of an iatrogenic visceral injury from the DPL procedure and to assess for gross M1 disease. Residual fluid from the DPL was collected and analyzed separately before performing peritoneal washings. Washings were performed in standard fashion by infusing 250 cm³ aliquots of normal saline into the left upper quadrant, right upper quadrant, and pelvis. The patient was gently agitated to allow for adequate sampling. Thirty centimeter cube samples of, fluid from each location was then collected and sent for cytologic analysis as a pooled sample (defined as DL-cyt). Cells that were deemed by our pathologists to be suspicious or definitive were categorized as positive cytology. Biopsies were performed to confirm M1 disease in the case of peritoneal or visceral metastasis.

Data collected included the time to perform DPL and DL and the volume of saline infused and collected with DPL. Comparisons were made between cytology results obtained with DPL (DPL-cyt) and

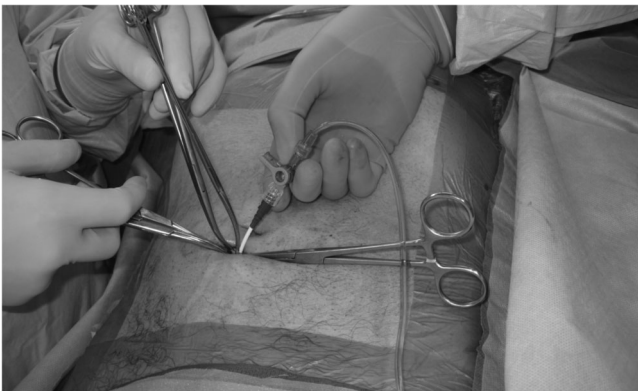

Fig. 1. Diagnostic peritoneal lavage.

those obtained with DL (DL-cyt). The sensitivity, specificity, negative and positive predictive value and accuracy of DPL for determining positive peritoneal cytology was determined. Complications from DPL and DL were collected for the immediate post-operative period and at 30 days after the procedure.

RESULTS

There were 27 patients enrolled from January 2007 to September 2009. Preoperative clinical variables are listed in Table I. All patients were staged with computed tomography (CT) and 22/27 patients (81%) had an endoscopic ultrasound as part of their staging workup. Clinical staging was determined based on a combination of EUS and CT findings. Two patients had trace ascites identified on their preoperative CT scans without gross solid organ metastases.

Figure 2 demonstrates the outcomes of DPL and subsequent DL. As shown in Figure 2, there were 5 (18.5%) technical failures of DPL. In four cases, adhesions precluded adequate inflow and efflux of fluid and in one case there was an inadequate sample and therefore was non-diagnostic. There were 22 DPLs performed successfully and results are shown in Table II. Twelve patients (4.5%) had positive cytology and 10 (45.5%) had negative cytology. DL was performed in all patients and cytology analysis completed in 26/27—the one patient that did not have cytology performed had peritoneal carcinomatosis. Among the five technical failures, three patients had negative DL-cyt, one patient had positive DL-cyt, and one patient did not have washing performed at DL.

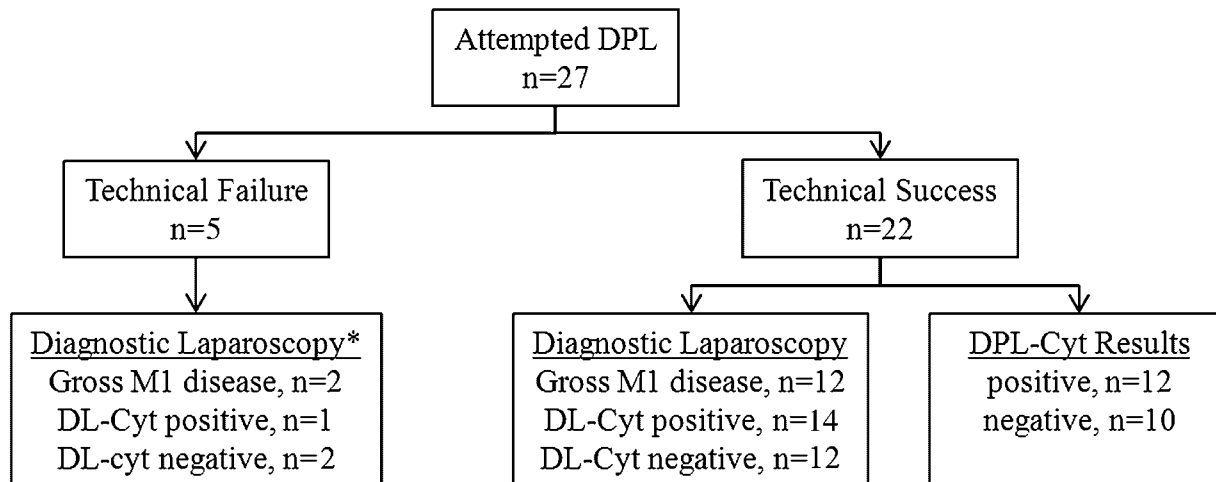
Based on these results and as shown in Table II, the sensitivity of DPL-cyt was 92% and specificity, 100%. Twelve/12 DPL-cyt patients also had positive cytology found on DL and therefore there were no false positive DPL-cyt results. There was one patient who had insufficient cells for analysis on DPL who had positive cytology on DL. There was one false negative DPL-cyt specimen in a patient with no evidence of gross M1 disease (DL-cyt was “suspicious for malignancy”).

Table III shows the outcomes of DPL and DL in patients found to have stage IV disease. DPL-cyt diagnosed M1 disease in 12 patients. One obvious limitation of cytologic analysis with DPL is the inability to visually assess the peritoneal cavity. There were 12 patients

TABLE I. Preoperative Clinicopathologic Variables of 27 Patients With Gastric Cancer

Variable	N (%)
Male	14 (52)
Median age, years (range)	63 (39–83)
Previous abdominal surgery	15 (56%)
Tumor location	
Gastroesophageal junction (Type III)	9 (33)
Cardia	8 (30)
Antrum	10 (37)
Preoperative staging studies	
Computed tomography	27 (100)
Endoscopic ultrasound	22 (81)
Clinical evidence of advanced disease	
Ascites	2 (7)
Gastric wall thickening	14 (52)
Lymphadenopathy	20 (74)
Preoperative clinical stage	
≤T2, node negative	4 (15)
≥T3, node positive	23 (85)
M1	2 (7) ^a

^aAscites noted on endoscopic ultrasound.



*one patient did not have cytology performed at diagnostic laparoscopy due to findings of carcinomatosis

Fig. 2. Outcomes of diagnostic peritoneal lavage and diagnostic laparoscopy in 27 patients with gastric cancer.

who were found to have gross M1 disease on DL (11 patients had carcinomatosis and 1 patient had liver metastasis). Three of these patients had negative DPL-cyt, six had positive DPL cyt and the other three patients did not have DPL-cyt performed.

TABLE II. DPL Results in 27 Prospectively Enrolled Patients With Gastric Cancer

Variable	N (%)
Technically successful DPL	22 (81.5)
Median time to complete DPL, min (range)	15 (5–35)
Immediate and 30-day surgical complications	0 (0)
DPL cytology (DPL-cyt)	N = 22
Positive	12 (54.5)
Negative	10 (45.5)
Diagnostic laparoscopy cytology (DL-cyt)	N = 27
Positive	14 (53.8)
Negative	12 (44.4)
Washings not performed	1 (3.8)
DPL cytology results (DL cytology control)	N = 22
True positives	12/12
True negatives	9/10
DPL evaluation of cytology (using DL as control)	
Sensitivity	12/13 (92.3)
Specificity	10/10 (100)
Positive predictive value	12/12 (100)
Negative predictive value	10/11 (91.0)
Accuracy	21/22 (95.5)
Findings at DL	N = 27
Positive cytology ^a	14 (51.9)
Gross M1 disease	12 (44.4)
Liver metastasis	1 (3.7)
Peritoneal carcinomatosis	11 (40.7)
DPL evaluation of M1 disease (using DL as control)	N = 22
Sensitivity	12/22 (54.5)
Specificity	10/10 (100)
Positive predictive value	12/12 (100)
Negative predictive value	6/10 (60.0)
Accuracy	18/22 (81.8)

^aOne patient did not have cytology performed at DL.

DISCUSSION

Positive peritoneal cytology is an independent predictor of uniformly poor outcome in gastric cancer staging and is now considered M1 disease by the AJCC [1,4,5]. As part of the staging workup for locally advanced gastric cancer, diagnostic laparoscopy is recommended for both assessment of cytology status and occult M1 disease. This approach may also spare patients non-therapeutic laparotomy when M1 disease is discovered [13]. Patients with M1 disease, whether it be cytology alone or gross peritoneal or visceral metastasis, generally do not undergo formal gastric resection. Therefore a clinical test to document M1 disease without the need for general anesthesia and diagnostic laparoscopy would be preferable in select patients. Cytology can also accurately stage patients being considered for clinical trials of neoadjuvant or perioperative chemotherapy.

Currently, multiple staging modalities exist for solid tumors. Streamlining the staging process would be preferable in the evidence-based approach to cancer patients. This can be facilitated first by selecting patients carefully to increase the yield of diagnostic laparoscopy [14]. Power and colleagues retrospectively evaluated the use of EUS as a guide for selecting patients for diagnostic laparoscopy prior to treatment of gastric cancer. They divided patients into low risk (T1–2, N0) and high risk (T3–4, N+, or both) for occult M1 disease based on EUS. Among the low risk patients, the yield of diagnostic laparoscopy was 4% (1/26 patients) compared to 25% (17/68 patients) for those deemed high risk. This is an example of how selecting patients specifically based on preoperative stage can increase the yield and negative predictive value of a staging modality.

One of the obvious limitations of DPL is the inability to visually inspect the peritoneal cavity. There were 12 patients in our study that had gross M1 disease found at laparoscopy, which included 1 patient with liver metastasis and 11 patients with peritoneal disease. Among these patients, six had positive cytology found on DPL. However, among the patients with *gross M1 disease*, there were six patients who had either negative DPL-cyt (n = 3) or a technical failure of DPL (n = 3). Thus DPL is an insensitive test for M1 disease overall (sensitivity 54.5% among technically successful procedures). These

TABLE III. Post-Operative AJCC Stage IV Patients (n = 19)

Patient #	Preoperative clinical stage	DPL technically successful	DPL cytology (DPL-cyt)	Control cytology (DL-cyt)	Gross M1 disease on DL	First evidence for pathologic stage IV disease
2	IIB	Y	+	+	Y	DPL-cyt
4	IIB	N	Failed	–	Y	DL (hepatic metastasis)
5	IIB	Y	–	–	Y	DL (carcinomatosis)
6	IV	Y	+	+	N	DPL-cyt
8	IIB	Y	+	+	N	DPL-cyt
9	IB	Y	+	+	Y	DPL-cyt
10	IB	Y	+	+	N	DPL-cyt
11	IIB	Y	+	+	N	DPL-cyt
12	IIB	Y	–	–	Y	DL (carcinomatosis)
13	IIB	Y	–	+	N	DL-cyt
15	IV	Y	+	+	Y	DPL-cyt
16	IIB	N	Failed	NP	Y	DL (carcinomatosis)
17	IIB	Y	+	+	Y	DPL-cyt
18	IIB	Y	+	+	Y	DPL-cyt
19	IIB	Y	+	+	N	DPL-cyt
21	IIA	Y	–	–	Y	DL (carcinomatosis)
23	IIB	Y	+	+	N	DPL-cyt
24	IIB	Y	+	+	Y	DPL-cyt
27	IIB	N	Failed	+	Y	DL (carcinomatosis)

DPL, diagnostic peritoneal lavage; DL, diagnostic laparoscopy; NP, not performed.

appear to be the two main limitations of this approach—technical feasibility and inability to visualize the peritoneal cavity. There are several factors that may account for these observations. First, the number of patients who were found to have gross M1 disease in this study (12/27, 44.4%) is high for patients with locally advanced gastric cancer without clinical evidence for M1 disease. Large retrospective series have demonstrated the yield of diagnostic laparoscopy in staging locally advanced gastric cancer to range from 13% to 40% [13]. Approximately one-third of these patients had tumors at the gastroesophageal junction, which has been shown to correlate with a higher rate of M1 disease found at diagnostic laparoscopy [14]. Furthermore not all patients with peritoneal carcinomatosis have positive peritoneal cytology, which may be due to sampling error [4].

At the onset of this study, we hypothesized that DPL could potentially streamline staging by being performed at the time of EUS or in an outpatient clinic with mild sedation. From this study, it appears that the best potential candidates for DPL would be patients without prior abdominal surgery who have locally advanced gastric cancer without evidence for M1 disease on high quality cross sectional imaging. Additionally, the patients are being treated with chemotherapy and there is no plan for an operation until the completion of therapy. At the time of a proposed resection, DL could be performed to evaluate for gross disease. Using more specific criteria to categorize patients as “high risk” may also increase the yield of DPL-cyt [9]. Additional methods to improve the sensitivity of DPL in this setting would be the use of RT-PCR for markers such as carcinoembryonic antigen in peritoneal washings [15]. Overall a larger series of patients (which may require a multi-institutional study) would be required to determine the optimal patient population for DPL.

This study has several limitations. Many of the patients had prior abdominal surgery, and although this has been shown to not reduce the yield of DL in the trauma setting, it may have an impact on the ability to perform DPL successfully in certain patients. This study also included a small number of patients from a single center and included two patients (7.4%) with suspicion for M1 disease based on imaging. Furthermore the DPL was performed under general anesthesia so the general application and feasibility of this procedure in an outpatient setting remains to be determined.

In conclusion, we have demonstrated that DPL is a safe technique for determining the status of peritoneal cytology in patients with

advanced gastric cancer. Despite a high sensitivity and specificity, the potential to miss occult gross M1 disease may limit the use of this diagnostic modality in staging gastric cancer and therefore DL remains the optimal method of staging in these patients.

REFERENCES

- Bentrem D, Wilton A, Mazumdar M, et al.: The value of peritoneal cytology as a preoperative predictor in patients with gastric carcinoma undergoing a curative resection. *Ann Surg Oncol* 2005;12:347–353.
- Homma Y, Ushida S, Yamada M, et al.: Positive peritoneal washing cytology in multiple cavities can predict poor prognosis of advanced gastric cancer patients. *Ann Surg Oncol* 2010;17:455–460.
- Lorenzen S, Panzram B, Rosenberg R, et al.: Prognostic significance of free peritoneal tumor cells in the peritoneal cavity before and after neoadjuvant chemotherapy in patients with gastric carcinoma undergoing potentially curative resection. *Ann Surg Oncol* 2010;17:2733–2739.
- Mezhir JJ, Shah MA, Jacks LM, et al.: Positive peritoneal cytology in patients with gastric cancer: Natural history and outcome of 291 patients. *Ann Surg Oncol* 2010;17:3173–3180.
- American Joint Committee on Cancer, 7th edition. New York: Springer; 2010.
- Lee SD, Ryu KW, Eom BW, et al.: Prognostic significance of peritoneal washing cytology in patients with gastric cancer. *Br J Surg* 2012;99:397–403.
- Cunningham D, Allum WH, Stenning SP, et al.: Perioperative chemotherapy versus surgery alone for resectable gastroesophageal cancer. *N Engl J Med* 2006;355:11–20.
- Okabe H, Ueda S, Obama K, et al.: Induction chemotherapy with S-1 plus cisplatin followed by surgery for treatment of gastric cancer with peritoneal dissemination. *Ann Surg Oncol* 2009;16:3227–3236.
- Power DG, Schattner MA, Gerdes H, et al.: Endoscopic ultrasound can improve the selection for laparoscopy in patients with localized gastric cancer. *J Am College Surg* 2009;208:173–178.
- Root HD, Hauser CW, McKinley CR, et al.: Diagnostic peritoneal lavage. *Surgery* 1965;57:633–637.
- Rozycki GS, Root HD: The diagnosis of intraabdominal visceral injury. *J Trauma* 2010;68:1019–1023.

12. Nagy KK, Roberts RR, Joseph KT, et al.: Experience with over 2500 diagnostic peritoneal lavages. *Injury* 2000;31:479–482.
13. Karanicolas PJ, Elkin EB, Jacks LM, et al.: Staging laparoscopy in the management of gastric cancer: A population-based analysis. *J Am College Surg* 2011;213:644–651, 51 e1.
14. Sarela AI, Lefkowitz R, Brennan MF, et al.: Selection of patients with gastric adenocarcinoma for laparoscopic staging. *Am J Surg* 2006;191:134–138.
15. Wong J, Kelly KJ, Mitra A, et al.: Rt-PCR increases detection of submicroscopic peritoneal metastases in gastric cancer and has prognostic significance. *J Gastrointest Surg* 2012;16:889–896.