

Histomolecular Phenotypes and Outcome in Adenocarcinoma of the Ampulla of Vater

David K. Chang, Nigel B. Jamieson, Amber L. Johns, Christopher J. Scarlett, Marina Pajic, Angela Chou, Mark Pinese, Jeremy L. Humphris, Marc D. Jones, Christopher Toon, Adnan M. Nagrial, Lorraine A. Chantrill, Venessa T. Chin, Andreia V. Pinho, Ilse Rooman, Mark J. Cowley, Jianmin Wu, R. Scott Mead, Emily K. Colvin, Jaswinder S. Samra, Vincenzo Corbo, Claudio Bassi, Massimo Falconi, Rita T. Lawlor, Stefano Crippa, Nicola Sperandio, Samantha Bersani, Euan J. Dickson, Mohamed A.A. Mohamed, Karin A. Oien, Alan K. Foulis, Elizabeth A. Musgrove, Robert L. Sutherland, James G. Kench, C. Ross Carter, Anthony J. Gill, Aldo Scarpa, Colin J. McKay, and Andrew V. Biankin

Author affiliations appear at the end of this article.

Published online ahead of print at www.jco.org on February 25, 2013.

Written on behalf of the Australian Pancreatic Cancer Genome Initiative.

Supported by the National Health and Medical Research Council of Australia, Cancer Council New South Wales (NSW), Cancer Institute NSW, Royal Australasian College of Surgeons, St Vincent's Clinic Foundation, R.T. Hall Trust, and Avner Nahmani Pancreatic Cancer Foundation, Australia; the Chief Scientist's Office of the Scottish Government, United Kingdom; and the Italian Association for Cancer Research, Fondazione Cariverona, and Miriam Cherubini Loro, Italy.

D.K.C., N.B.J., A.S., C.J.M., and A.V.B. contributed equally to this work.

Presented at the 41st American Pancreatic Association Annual Meeting, Chicago, IL, November 3-6, 2010, and American Society of Clinical Oncology Gastrointestinal Cancer Symposium, San Francisco, CA, January 20-22, 2011.

Authors' disclosures of potential conflicts of interest and author contributions are found at the end of this article.

Corresponding author: Andrew V. Biankin, BMedSc, MBBS, PhD, Cancer Research Program, Garvan Institute of Medical Research, 384 Victoria St, Darlinghurst, Sydney, NSW 2010 Australia; e-mail: a.biankin@garvan.org.au.

© 2013 by American Society of Clinical Oncology

0732-183X/13/3110-1348/\$20.00

DOI: 10.1200/JCO.2012.46.8868

ABSTRACT

Purpose

Individuals with adenocarcinoma of the ampulla of Vater demonstrate a broad range of outcomes, presumably because these cancers may arise from any one of the three epithelia that converge at that location. This variability poses challenges for clinical decision making and the development of novel therapeutic strategies.

Patients and Methods

We assessed the potential clinical utility of histomolecular phenotypes defined using a combination of histopathology and protein expression (CDX2 and MUC1) in 208 patients from three independent cohorts who underwent surgical resection for adenocarcinoma of the ampulla of Vater.

Results

Histologic subtype and CDX2 and MUC1 expression were significant prognostic variables. Patients with a histomolecular pancreaticobiliary phenotype (CDX2 negative, MUC1 positive) segregated into a poor prognostic group in the training (hazard ratio [HR], 3.34; 95% CI, 1.69 to 6.62; $P < .001$) and both validation cohorts (HR, 5.65; 95% CI, 2.77 to 11.5; $P < .001$ and HR, 2.78; 95% CI, 1.25 to 7.17; $P = .0119$) compared with histomolecular nonpancreaticobiliary carcinomas. Further stratification by lymph node (LN) status defined three clinically relevant subgroups: one, patients with histomolecular nonpancreaticobiliary (intestinal) carcinoma without LN metastases who had an excellent prognosis; two, those with histomolecular pancreaticobiliary carcinoma with LN metastases who had a poor outcome; and three, the remainder of patients (nonpancreaticobiliary, LN positive or pancreaticobiliary, LN negative) who had an intermediate outcome.

Conclusion

Histopathologic and molecular criteria combine to define clinically relevant histomolecular phenotypes of adenocarcinoma of the ampulla of Vater and potentially represent distinct diseases with significant implications for current therapeutic strategies, the ability to interpret past clinical trials, and future trial design.

J Clin Oncol 31:1348-1356. © 2013 by American Society of Clinical Oncology

INTRODUCTION

Adenocarcinoma of the ampulla of Vater is the second most common malignancy of the periampullary region and accounts for up to 30% of all pancreaticoduodenectomies.^{1,2} The broad range of outcomes for patients with adenocarcinoma of the ampulla of Vater³⁻⁸ impairs the interpretation of clinical trials and hampers clinical decision making. This is perhaps not surprising, because they may arise from any one of the three epithelia (duodenal, biliary, or pancreatic) that converge at this location.

The inability to predict individual outcomes for cancers in this anatomic location has made aspects of clinical decision making difficult with regard to the aggressiveness of therapy and the choice of appropriate chemotherapeutic strategies. Randomized, controlled trials⁹⁻¹¹ and single-institution cohorts¹²⁻¹⁸ grouping all adenocarcinomas together have failed to definitively demonstrate a survival benefit for adjuvant chemotherapy. Some studies have suggested that adenocarcinoma of the ampulla of Vater may be subdivided based on histologic appearances^{19,20} and GI markers such as caudal-type

homeodomain transcription factors, apomucins, and cytokeratins²¹⁻²³; however, the potential clinical utility of such a classification has not been investigated.

This is problematic in interpreting clinical trial data because different phenotypes are likely to have a differential response to specific chemotherapeutics. Although both gemcitabine and fluorouracil (FU) may be effective in pancreatic cancer, gemcitabine is not known for its efficacy in carcinomas of intestinal origin.²⁴ For example, the ESPAC-3 (V2) adjuvant therapy trial compared adjuvant FU with gemcitabine or observation for resected ampullary cancer; despite an overall survival benefit with adjuvant chemotherapy on multivariate analysis, there was no difference in response between pancreaticobiliary and intestinal subtypes based on histology alone in a posthoc analysis.²⁵

Here, we validate previously described prognostic factors²¹ and define distinct phenotypes of adenocarcinoma of the ampulla of Vater based on a combination of molecular and histopathologic features using three independent cohorts of patients. Such histomolecular stratification may better delineate prognostic groups, aid in the refinement of current therapeutic strategies, better interpret past clinical trials, and facilitate future trial design.

PATIENTS AND METHODS

Patients and Data Acquisition

Training cohort. Clinicopathologic and outcome data for a cohort of 72 consecutive patients with a diagnosis of adenocarcinoma of the ampulla of Vater who underwent Whipple's pancreaticoduodenectomy with curative

intent between 1993 and 2008 were accrued from six teaching hospitals associated with the Australian Pancreatic Cancer Genome Initiative (APGI; www.pancreaticcancer.net.au), Sydney, New South Wales, Australia (online-only Appendix; Table 1; Data Supplement). This was designated the Sydney training cohort.

Validation cohorts. Two additional cohorts of 90 and 46 patients, respectively, were prospectively acquired at the West of Scotland Pancreatic Unit, Glasgow Royal Infirmary, Glasgow, United Kingdom (between 1992 and 2010), and the University Hospital of Verona, Verona, Italy (between 1992 and 2010). These were designated as the Glasgow validation cohort and the Verona validation cohort, respectively. Ethical approval for the acquisition of data and biologic material was obtained from the human research ethics committee at each participating institution (Appendix, online only). Informed consent was obtained from each participant for the validation cohorts but was not required by the human research ethics committee for the retrospective patient cases in the Sydney cohort.

Adenocarcinoma of the ampulla of Vater was verified and all pathologic features reviewed independently by two specialist pancreatic histopathologists who were blinded to clinical outcomes. This was performed by A.J.G. and A.C. for the Sydney training cohort, A.K.F. and K.A.O. for the Glasgow validation cohort, and A.J.G. and A.S. for the Verona validation cohort. Tumors were classified as either of intestinal, pancreaticobiliary, or mixed histologic subtype. The intestinal histologic subtype was defined by tall columnar cells forming elongated glands (similar to colorectal adenocarcinoma), whereas pancreaticobiliary morphology was defined by cells with rounded nuclei forming rounded glands, similar to the majority of pancreaticobiliary carcinomas (Figs 1A to 1F). Mixed tumors contained > 10% of both histologic types and overall accounted for only 7% of samples. Tumors were staged according to the American Joint Committee on Cancer (AJCC) Staging Manual, seventh edition.²⁶

Tissue Microarrays and Immunohistochemistry

Tissue microarrays were constructed from formalin-fixed, paraffin-embedded material, with each specimen represented by a minimum of 3- × 1-mm tissue cores. Immunohistochemistry was performed

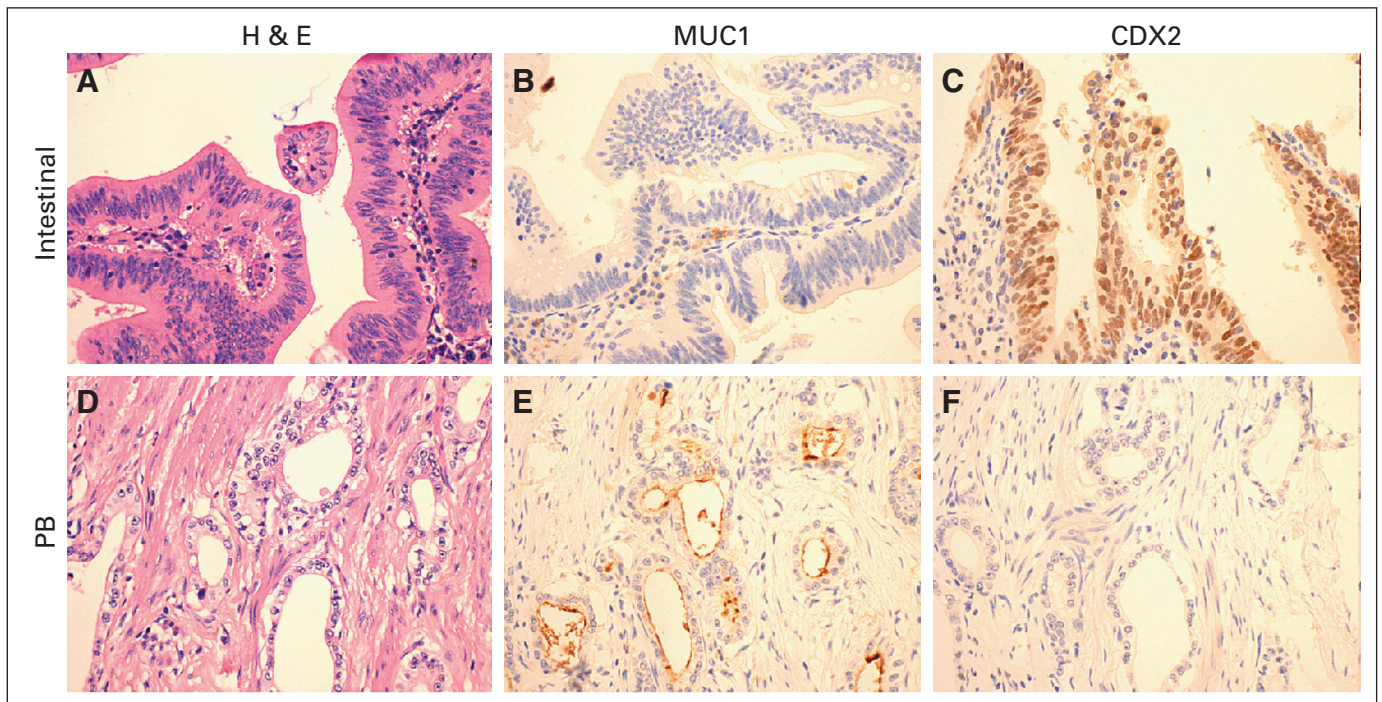


Fig 1. Serial sections stained with hematoxylin and eosin (H & E). (A, B, C) MUC1 and CDX2 in one patient case displaying the typical histomolecular intestinal phenotype, and (D, E, F) one patient case displaying the typical histomolecular pancreaticobiliary (PB) phenotype. (A) The intestinal-type morphology is characterized by tall columnar cells forming elongated glands, (B) negative for MUC1 with (C) positive nuclear CDX2 immunostaining, whereas (D) pancreaticobiliary morphology is characterized by cells with rounded nuclei forming rounded glands, (E) with positive apical MUC1 immunostaining and (F) negative CDX2. All original magnifications at ×400.

on 4- μ m serial sections mounted on SuperFrost slides (Menzel-Gläser, Braunschweig, Germany).

CDX2, MUC1, MUC2, CK7, and CK20 Immunohistochemistry

Five routinely used immunohistochemical markers were examined based on their routine use to define the origin of adenocarcinomas where the primary site of carcinoma is unknown (cytokeratins CK7 and CK20 and epithelial mucins MUC1 and MUC2^{27,28}) or to distinguish adenocarcinomas of intestinal type from tumors that arise elsewhere (CDX2).²⁹ The Appendix (online only) provides information for each antibody, dilution, and retrieval method. All five biomarkers were tested in the Sydney training cohort, but only the two that were prognostic (CDX2 and MUC1) were tested in the validation cohorts.

Immunohistochemistry Scoring

Immunostaining (Figs 1A to 1F) was scored semiquantitatively as follows: 0 (absent staining), 1+ (focal weak staining), and 2+ (strong diffuse staining). For CDX2, in addition to intensity (0 to 3), the percentage of positive staining cells was also determined. Standardization of scoring was achieved by comparison of scores between at least two specialist pancreatic histopathologists and/or translational researchers experienced in peripancreatic pathology (A.J.G., A.S., and A.C. for Sydney and Verona cohorts; A.K.F., K.A.O., N.B.J., and M.A.A.M. for the Glasgow cohort). Any discrepancies were resolved by consensus after conferencing. Positive CDX2 expression was defined as a modified H score (intensity \times percentage of positive cells) of > 35 . Positive MUC1, MUC2, and CK20 expression was defined as any positive staining; positive CK7 expression was defined as staining intensity of 2.

Statistical Analysis

Median survival was estimated using the Kaplan-Meier method, and the difference was tested using the log-rank test. The 5-year survival rate was estimated using the life-table method. *P* values $< .05$ were considered statistically significant. Clinicopathologic variables analyzed with a *P* value $< .25$ on log-rank test were entered into Cox proportional hazards multivariate analysis. Statistical analysis was performed using StatView 5.0 software (Abacus Systems, Berkeley, CA). Overall (Sydney and Verona cohorts) and disease-specific survival (Glasgow cohort) were used as the primary end points.

RESULTS

Cohort Characteristics

Characteristics of all cohorts are summarized in Table 1, with detailed descriptions provided in the Data Supplement.

Clinicopathologic and Molecular Prognostic Factors

Sydney training cohort. Factors associated with better survival on univariate analysis included T1/T2 tumors compared with T3/T4 tumors (median survival, 152.4 v 57.0 months; *P* = .0334), absence of lymph node metastases (152.4 v 32.1 months; *P* = .0011), and tumors of histopathologic intestinal or mixed subtype compared with pancreaticobiliary subtype (115.5 v 22.0 months; *P* = .0169; mixed tumors were grouped with the intestinal subtype). The overall AJCC pathologic stage was also associated with outcome, with median survival for stages I, II, and III of 152.4, 69.5, and 20.5 months, respectively (*P* = .003). Adjuvant chemotherapy was administered to 17 patients and was not associated with improved survival (median survival, 57.0 v 72.0 months; *P* = .7384). Of the five molecular markers examined (CDX2, MUC1, MUC2, CK7, and CK20), positive CDX2 expression (172.8 v 69.5 months; *P* = .0368) and negative MUC1 expression (115.5 v 45.0 months; *P* = .0315) were associated with longer survival (Table 1; Data Supplement).

Glasgow validation cohort. Factors associated with better survival on univariate analysis included T1/T2 tumors compared with

T3/T4 tumors (median survival, 90.4 v 26.2 months; *P* = .0097), absence of lymph node metastases (120.9 v 17.6 months; *P* $< .001$), well/moderate tumor differentiation (47.5 v 18.1 months; *P* = .0095), tumor size ≤ 20 mm (47.7 v 26.0 months; *P* = .0462), tumors of histopathologic intestinal or mixed subtype compared with pancreaticobiliary subtype (69.0 v 23.9 months; *P* $< .001$), and absence of vascular space invasion (47.7 v 13.6 months; *P* $< .001$). The overall AJCC pathologic stage was also associated with outcome, with median survival for stages I, II, and III of not applicable (NA), 27.0, and 11.1 months, respectively (*P* $< .001$; NA indicates median survival was not reached). Adjuvant chemotherapy was administered to 21 patients and was not associated with improved survival (median survival, 33.0 v 29.0 months; *P* = .6800). Positive CDX2 expression (NA v 24.2 months; *P* $< .001$) and negative MUC1 expression (67.0 v 20.1 months; *P* = .0055) were associated with longer survival (Table 1; Data Supplement).

Verona validation cohort. Factors associated with better survival on univariate analysis included absence of lymph node metastases (NA v 36.0 months; *P* = .0056) and tumors of histopathologic intestinal or mixed subtype compared with pancreaticobiliary subtype (94.0 v 33.3 months; *P* = .0246). The overall AJCC pathologic stage was also associated with outcome, with median survival for stages I, II, and III of NA, 102.3, and 32.0 months, respectively (*P* = .0019). Positive CDX2 expression (94.0 v 33.3 months; *P* = .0966) and negative MUC1 expression (NA v 36.0 months; *P* $< .001$) trended with or was associated with better survival (Table 1; Data Supplement).

Histopathologic and Molecular Criteria Combine to Define Distinct Phenotypes of Adenocarcinoma of the Ampulla of Vater

CDX2 is a transcription factor that regulates axial development and intestinal differentiation, is expressed almost exclusively in intestinal epithelium,^{29,30} and is associated with better survival in ampullary cancers.²¹ Conversely, MUC1 expression is highly prevalent in cancers of pancreaticobiliary origin.^{28,31} On the basis of the hypothesis that these markers represent different molecular phenotypes, the histologic subtypes were combined with differential marker expression.

Patients were grouped into the histomolecular pancreaticobiliary or nonpancreaticobiliary (intestinal) phenotype. The pancreaticobiliary phenotype was defined as a tumor of histologic pancreaticobiliary subtype with negative CDX2 and positive MUC1 immunostaining. The nonpancreaticobiliary (intestinal) phenotype encompassed the remainder. In the Sydney training cohort, a histomolecular pancreaticobiliary phenotype was associated with a poor prognosis on both univariate (median survival, 16.1 v 115.5 months; *P* $< .001$; Table 1; Fig 2A) and multivariate analyses (HR, 3.40; 95% CI, 1.71 to 6.76; *P* $< .001$; Table 2; Data Supplement). The only other independent prognostic factor was the presence of lymph node metastases (HR, 3.19; 95% CI, 1.54 to 6.58; *P* = .0017). These two independent prognostic variables were used to stratify the cohort into three prognostic groups (Fig 2D). First, the group of patients with a histomolecular nonpancreaticobiliary (intestinal) phenotype and no lymph node involvement had an excellent prognosis, with a 5-year survival of 88.4% and median survival of 172.8 months. Second, the group of patients with a histomolecular pancreaticobiliary phenotype and lymph node metastases had a poor prognosis, with a 5-year survival of 20.0% and median survival of 7.4 months. Third, the remaining patients (histomolecular nonpancreaticobiliary [intestinal] phenotype with lymph

Molecular Pathologic Phenotypes and Outcome in Ampullary Cancer

Table 1. Clinicopathologic Parameters and Outcome for All Cohorts

Variable	Sydney Cohort (n = 72)				Glasgow Cohort (n = 90)				Verona Cohort (n = 46)			
	No.	%	Median OS (months)	Log-Rank P	No.	%	Median DSS (months)	Log-Rank P	No.	%	Median OS (months)	Log-Rank P
Sex				.6779				.5411				.0475
Male	42	58.3	72.7		53	58.9	33.0		25	54.3	36.0	
Female	30	41.7	152.4		37	41.1	28.3		21	45.7	102.3	
Age, years												
Mean			66.1				63.5				62.9	
Median			68.0				65.1				64.0	
Range			34.0-88.0				37.7-77.5				38.0-79.0	
Follow-up												
Median			84.0				81.0				105.9	
Range			0.3-193				0.4-240.0				7.0-145.1	
Outcome												
Death AC	30	41.6			54	60.0			25	54.3		
Death other	4	5.6			7	7.8			2	4.3		
Death unknown	2	2.8			0	0.0			0	0.0		
Alive	36	50.0			29	32.2			19	41.3		
Overall stage				.0030				< .001				.0019
I	17	23.6	152.4		19	21.1	NA		7	15.2	NA	
II	39	54.2	69.5		55	61.1	27.0		17	37.0	102.3	
III	16	22.2	20.5		16	17.8	11.1		22	47.8	32.0	
T stage				.0334*				.0097*				.1248*
T1	10	13.9			6	6.7			2	4.3		
T2	20	27.8	152.4		31	34.4	90.4		7	15.2	NA	
T3	26	36.1			37	41.1			12	26.1		
T4	16	22.2	57.0		16	17.8	26.2		25	54.3	43.9	
N stage				.0011				< .001				.0056
N0	36	50.0	152.4		39	43.3	120.9		16	34.8	NA	
N1	36	50.0	32.1		51	56.7	17.6		30	65.2	36.0	
Grade				.1063†				.0095†				.3066†
I	6	8.3			4	4.4			2	4.3		
II	35	48.6	101.4		57	63.3	47.5		33	71.7	51.9	
III	28	38.9			29	32.2			10	21.7		
IV	3	4.2	25.1		0	0.0	18.1		1	2.2	33.3	
Tumor size, mm				.9858				.0462				.0152
≤ 20	37	51.4	72.0		45	50.0	47.7		7	15.2	19.0	
> 20	35	48.6	115.5		45	50.0	26.0		39	84.8	69.9	
Margins‡				.5205				.0776				.9490
Clear	68	94.4	101.4		61	67.8	35.0		40	87.0	51.8	
Involved	4	5.6	20.5		29	32.2	27.5		6	13.0	62.0	
Subtype				.0169§				< .001§				.0246§
Intestinal	41	56.9			44	48.9			20	43.5		
Mixed	5	6.9	115.5		5	5.6	69.0		4	8.7	94.0	
Pancreaticobiliary	26	36.1	22.0		41	45.6	23.9		22	47.8	33.3	
Perineural invasion				.3216				.0623				.0510
Negative	52	72.2	101.4		60	66.7	32.1		22	47.8	94.0	
Positive	20	27.8	57.0		30	33.3	23.9		24	52.2	42.3	
Vascular invasion				.0818				< .001				.0817
Negative	22	30.6	115.5		63	70.0	47.7		23	50.0	94.0	
Positive	50	69.4	69.5		27	30.0	13.6		23	50.0	36.0	
Chemotherapy				.7384				.6800				.6256
Adjuvant	17	27.4	57.0		21	23.3	33.0		26	56.5	43.9	
No adjuvant	45	72.6	72.0		69	76.7	29.0		20	43.4	69.9	
CDX2 expression				.0368				< .001				.0966
Negative	51	70.8	69.5		54	65.0	24.2		18	40.0	33.3	
Positive	21	29.2	172.8		29	35.0	NA		27	60.0	94.0	
MUC1 expression¶				.0315				.0055				< .001
Negative	29	40.3	115.5		51	57.3	67.0		15	32.6	NA	
Positive	43	59.7	45.0		38	42.7	20.1		31	67.4	36.0	

(continued on following page)

Table 1. Clinicopathologic Parameters and Outcome for All Cohorts (continued)

Variable	Sydney Cohort (n = 72)				Glasgow Cohort (n = 90)				Verona Cohort (n = 46)			
	No.	%	Median OS (months)	Log-Rank <i>P</i>	No.	%	Median DSS (months)	Log-Rank <i>P</i>	No.	%	Median OS (months)	Log-Rank <i>P</i>
Histomolecular phenotype				< .001				< .001				.0088
Intestinal, CDX2 positive, or MUC1 negative	54	75.0	115.5		66	80.5	67.0		33	73.3	94.0	
PB, CDX2 negative, and MUC1 positive	18	25.0	16.1		16	19.5	11.9		12	26.7	30.9	
Histomolecular phenotype and LN status				< .001				< .001				< .001
Non-PB (intestinal), LN negative	28	43.9	172.8		36	43.9	NA		16	35.6	NA	
Non-PB (intestinal), LN positive or PB, LN negative	34	40.2	57.0		33	40.2	26.2		17	37.8	51.8	
PB, LN positive	10	15.9	7.4		13	15.9	11.9		12	26.7	30.9	

Abbreviations: AC, ampullary cancer; DSS, disease-specific survival; LN, lymph node; NA, not applicable (median survival not reached); OS, overall survival; PB, pancreaticobiliary.

*T1/2 versus T3/4 for survival analyses based on American Joint Committee on Cancer TNM Staging System, Ampullary Cancer.

†Grade I/II versus III/IV for survival analyses.

‡Microscopically involved margin (R1) is defined as 0 mm in the Sydney and Verona cohorts and as 1 mm in the Glasgow cohort.

§Intestinal and mixed subtypes versus PB subtype for survival analyses.

||Positive expression of CDX2 was defined as modified H score > 35.

¶Positive expression of MUC1 was defined as any staining.

node metastases or histomolecular pancreaticobiliary phenotype with no lymph node involvement) had an intermediate prognosis, with a 5-year survival of 46.9% and median survival of 57.0 months.

The poorest prognostic histomolecular phenotypic subgroup (pancreaticobiliary subtype, CDX2 negative and MUC1 positive) was defined using a combination of both histologic and molecular criteria. Using the same concept, although the numbers were small, the best prognostic phenotypic subgroup could also be identified. Patients who had a tumor of histomolecular intestinal phenotype (histological intestinal subtype and CDX2 positive) with no lymph node metastases had an extremely good prognosis, with a 5-year survival of 100% and median survival of 172.8 months (Data Supplement). To validate these findings, two comparable but independent cohorts of patients with resected adenocarcinoma of the ampulla of Vater were examined using identical histologic and molecular criteria.

Glasgow validation cohort. Histomolecular phenotypes defined in the Sydney training cohort cosegregated with outcomes (histomolecular nonpancreaticobiliary *v* pancreaticobiliary; median survival, 67.0 *v* 11.9 months; *P* < .001; Fig 2B). Further stratification with lymph node status again stratified the cohort into three distinct prognostic groups, recapitulating the findings of the Sydney training cohort (Fig 2E). First, the group of patients with histomolecular nonpancreaticobiliary (intestinal) phenotype and no lymph node involvement again had an excellent prognosis, with a 5-year survival of 66.7% and median survival that was not reached. Second, the group of patients with a histomolecular pancreaticobiliary phenotype and lymph node metastases had a poor prognosis, with a median survival of 11.9 months and no 5-year survivors. Third, the remaining patients had an intermediate prognosis, with a 5-year survival of 28.6% and median survival of 26.2 months. Once again, patients with a histomolecular intestinal phenotype without lymph node metastases had an extremely good prognosis, with a 5-year survival of 90% and median survival that was not reached (Data Supplement).

Verona validation cohort. These relationships with outcome were also apparent in the Verona validation cohort. The two prognostic groups of histomolecular nonpancreaticobiliary and pancreatico-

biliary phenotypes had median survivals of 94.0 and 30.9 months, respectively (*P* = .0088; Fig 2C). Further stratification with lymph node status again divided the cohort into three distinct prognostic groups (Fig 2F). First, the group of patients with histomolecular nonpancreaticobiliary (intestinal) phenotype and no lymph node involvement again had an excellent prognosis, with a 5-year survival of 87.5% and median survival that was not reached. The other two groups had 5-year and median survivals of 41.7% and 51.8 months and 16.7% and 30.9 months, respectively. Patients with a histomolecular intestinal phenotype carcinoma without lymph node metastases again had a favorable prognosis (5-year survival, 92.3%; median survival, 102.3 months; Data Supplement). REMARK (Reporting Recommendations for Tumor Marker Prognostic Studies) criteria³² summaries for CDX2 and MUC1 are presented in Table 3.

DISCUSSION

Defining clinically and biologically relevant phenotypes leads to improvements in overall outcomes through facilitating clinical decision making. Here, we identify distinct clinically relevant phenotypes by refining a histologic classification with molecular criteria to define histomolecular phenotypes. These results were independently validated in two additional cohorts of patients, where histomolecular phenotyping again delineated these distinct prognostic groups. A robust histomolecular classification that is prognostic across several independent cohorts in a heterogeneous cancer type compared with conventional histopathologic classification indirectly supports its use over more variable clinicopathologic factors. Such variability in clinicopathologic factors was seen in these cohorts and has occurred even in large, phase III, randomized, controlled clinical trials, such as RTOG (Radiation Therapy Oncology Group) -9704, ESPAC (European Study Group for Pancreatic Cancer) -1, ESPAC-3, and CONKO (Charité Onkologie) -001. This classification is potentially important in a disease with a broad range of outcomes such as adenocarcinoma of the ampulla of Vater. First, patients could be better selected for

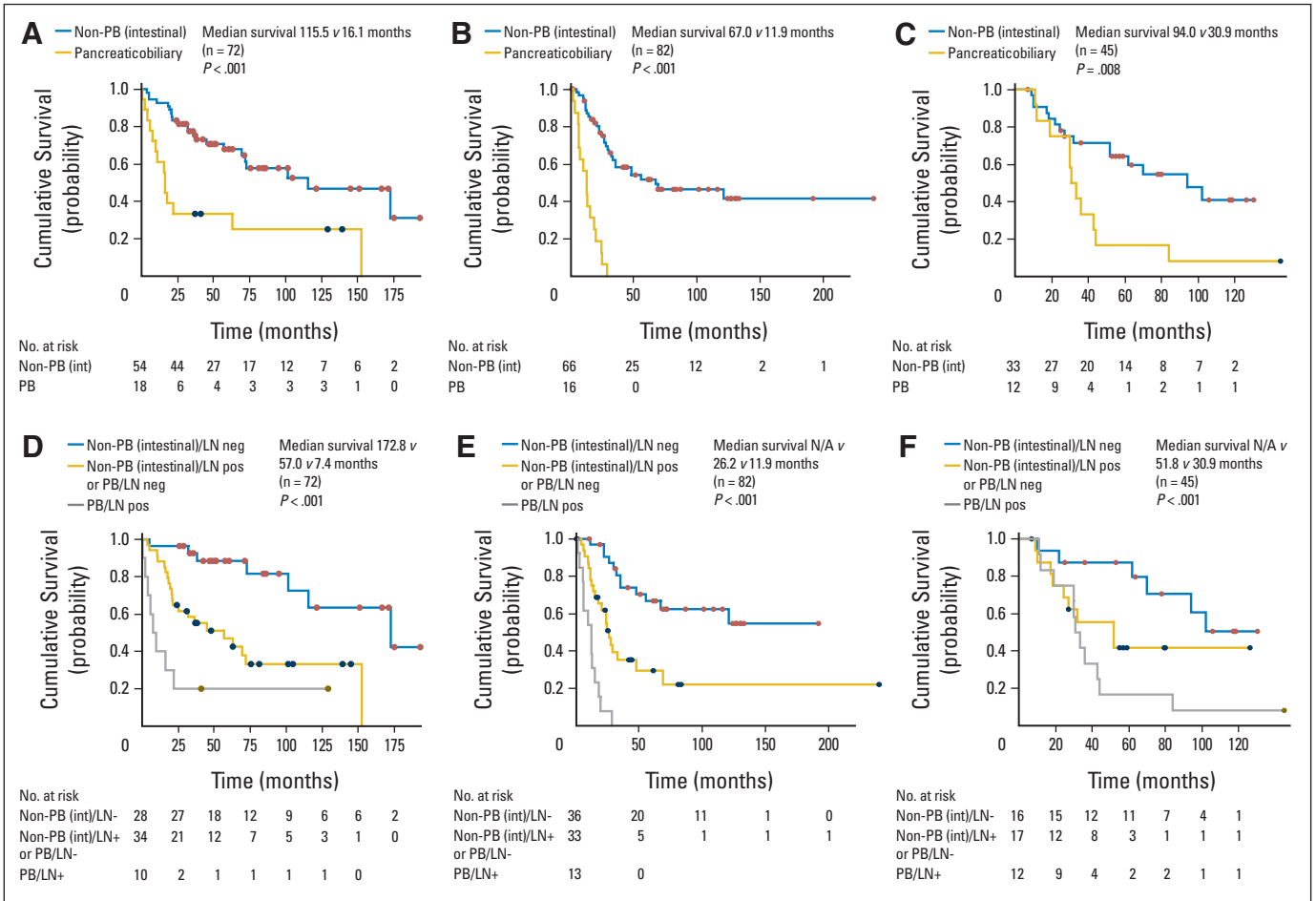


Fig 2. Kaplan-Meier survival curves for the (A, D) Sydney training cohort and (B, E) Glasgow and (C, F) Verona validation cohorts showing (A, B, C) histomolecular phenotypes and (D, E, F) subsequent stratification of each cohort into three prognostic phenotypes using histomolecular phenotyping and lymph node (LN) status. INT, intestinal; N/A, not applicable; OR, median survival not reached; PB, pancreaticobiliary.

surgery, so aggressive and radical surgery could be justified in patients with a tumor of histomolecular intestinal (nonpancreaticobiliary) phenotype on biopsy and a good prognosis expected if resected with clear margins. Second, patients could be better selected for adjuvant chemotherapy, because it is likely that they respond differently to different chemotherapeutic regimens and should be treated differently. Adjuvant gemcitabine chemotherapy would likely only benefit

the pancreaticobiliary phenotype, not the intestinal phenotype. This heterogeneity in response may also make it difficult to detect a statistically significant difference in clinical trials of unselected patients. The outcome of a trial would depend on the proportion of each phenotype within the recruited cohort, and the histomolecular distinction could be used to target specific patient subgroups. In addition, it is difficult to detect efficacy of an adjuvant strategy in patients who have an excellent prognosis with surgery alone, and the inclusion of such patients would inadvertently underpower clinical trials.

This could have contributed to the negative result of the ESPAC-3 (V2) adjuvant therapy trial for periampullary cancer,²⁵ where posthoc analysis based on histologic subtype alone did not identify differential treatment responsiveness. In addition, the potential benefit of adjuvant chemotherapy was only demonstrated in multivariate analysis when adjusted for other prognostic variables, suggesting that poor-prognosis tumors were potentially associated with responsiveness. This is also supported by evidence from single-institutional studies, showing a survival benefit with adjuvant chemotherapy in patients with unfavorable prognostic features.^{12,13,15-18} Additional analyses using a histomolecular classifier should be encouraged and may be informative because this would potentially better differentiate underlying tumor biology. In our cohorts, fewer than

Table 2. Multivariate Analyses: Final Models for All Cohorts

Variable	HR	95% CI	P
Sydney cohort (n = 72)			
Positive LN metastases	3.19	1.54 to 6.58	.0017
PB histomolecular phenotype	3.40	1.71 to 6.76	< .001
Glasgow cohort (n = 82)			
Tumor stage (T3/T4)	2.27	1.09 to 4.74	.0280
Positive LN metastases	2.63	1.36 to 5.10	.0042
PB histomolecular phenotype	5.65	2.77 to 11.5	< .001
Verona cohort (n = 45)			
Positive LN metastases	3.51	1.37 to 8.93	.0086

Abbreviations: HR, hazard ratio; LN, lymph node; PB, pancreaticobiliary.

Table 3. REMARK Summary for CDX2 and MUC1

Category	Summary
Introduction	
Markers examined	CDX2 (caudal type homeobox 2) MUC1 (Mucin 1, cell surface associated)
Objective	Assess potential of CDX2 and MUC1 expression as markers of prognosis in patients with adenocarcinoma of ampulla of Vater
Hypothesis	Tumor CDX2 and MUC1 protein expression cosegregates with differential outcomes and histologic subtypes
Patients and methods	
Patients	72 (Sydney training cohort), 90 (Glasgow validation cohort), and 46 (Verona validation cohort) consecutive patients who underwent pancreaticoduodenectomy for adenocarcinoma of ampulla of Vater with curative intent (AJCC stages 1 and 2, R0 or R1; Table 1; Data Supplement)
Specimen characteristics	TMAAs constructed from formalin-fixed, paraffin-embedded surgical specimens; each patient represented by 3- × 1-mm cores
Assay methods	Immunohistochemistry performed on TMAAs, which were scored by two independent assessors blinded to outcomes, both of whom are specialist pancreatic pathologists
Study design	Retrospective analysis of prospectively maintained database of cohorts of consecutive patients from hospitals associated with Australian Pancreatic Cancer Genome Initiative (Sydney, Australia) for Sydney training cohort; West of Scotland Pancreatic Unit, Glasgow Royal Infirmary, Glasgow, United Kingdom, for the Glasgow validation cohort; and University Hospital of Verona, Verona, Italy, for Verona validation cohort
Statistical analysis methods	End point, overall survival Clinicopathologic features summarized in Table 1 and Data Supplement Median survival estimated using Kaplan-Meier method; difference tested using log-rank test Clinicopathologic variables analyzed with $P < .25$ on log-rank test were entered into Cox proportional hazards multivariate analysis; models generated using backward elimination of redundant variables Patients were dichotomized into high/positive and low/negative: CDX2 expression groups based on modified H score (percentage of positive cells × intensity of staining) of 35 MUC1 expression groups based on any staining There were some missing biomarker data for a small number of patients because of loss of cores on TMAAs during processing; they were excluded from analyses; for Glasgow validation cohort, seven of 90 for CDX2 and one of 90 for MUC1; for Verona validation cohort, one of 46 for CDX2
Results	
Data	Clinicopathologic characteristics are comprehensively described in Table 1 and Data Supplement
Analysis and presentation	CDX2 expression associated with better prognosis on univariate analysis in both Sydney training (median survival, 172.8 v 69.5 months; $P = .0368$) and Glasgow validation cohorts (NA v 24.2 months; $P < .001$) and was borderline significant in Verona validation cohort (94.0 v 33.3 months; $P = .0966$) Absence of MUC1 expression associated with better prognosis on univariate analysis in all cohorts (Sydney training cohort: median survival, 115.5 v 45.0 months; $P = .0315$; Glasgow validation cohort: 67.0 v 20.1 months; $P = .0055$; Verona validation cohort: NA v 36.0; $P < .001$) When combining molecular and histologic subtypes, histomolecular PB phenotype (histologic PB, CDX2 negative, MUC1 positive) associated with poor prognosis compared with histomolecular non-PB (intestinal) phenotype on both univariate and multivariate analyses in Sydney training cohort (16.1 v 115.5 months; $P < .001$; HR, 3.40; 95% CI, 1.71 to 6.76; $P < .001$) and Glasgow validation cohort (11.9 v 67.0 months; $P < .001$; HR, 5.65; 95% CI, 2.77 to 11.5; $P < .001$); it was significant in only univariate analysis for Verona validation cohort (30.9 v 94.0 months; $P = .0088$)
Discussion	Differential CDX2 and MUC1 expression and combination of molecular and histologic criteria (histomolecular phenotype) cosegregated with prognosis in patients with adenocarcinoma of ampulla of Vater Histomolecular phenotyping defined two clinically relevant phenotypes of adenocarcinoma of ampulla of Vater, potentially representing two distinct diseases These two different phenotypes of prognosis and therapeutic responsiveness have potentially significant implications for current chemotherapeutic strategies, better interpretation of past clinical trials, and facilitation of future trial design
Abbreviations: AJCC, American Joint Committee on Cancer; HR, hazard ratio; NA, not applicable (median survival not reached); PB, pancreaticobiliary; REMARK, Reporting Recommendations for Tumor Marker Prognostic Studies; TMA, tissue microarray.	

one third of patients received adjuvant chemotherapy, and the chemotherapeutic agents used were variable, making interpretation difficult because of small numbers. These analyses did not reveal any association with response overall or differential response of subgroups to adjuvant therapy (data not shown).

Patients whose tumors had a histomolecular intestinal phenotype, without lymph node metastases, had an extremely favorable prognosis (approximately 85% at 5 years), and they could potentially be analogous to those with Dukes' A and Dukes' B colorectal cancers, where adjuvant chemotherapy can be avoided, presenting opportunities for decreasing treatment-associated morbidity and cost. However, patients stratified to the other two groups could be targeted aggressively, because their 5-year survival is relatively poor. Patients with

histomolecular pancreaticobiliary tumors could arguably be treated like those with adenocarcinoma of the pancreas and biliary tree, and gemcitabine-based chemotherapy could be used regardless of lymph node status. On the other hand, patients with histomolecular intestinal (nonpancreaticobiliary) tumors with lymph node metastases could be treated like those with Dukes' C colorectal cancer, and FU plus leucovorin-based chemotherapy could be used. These approaches may be used to better interpret past clinical trials and better define phenotypes of therapeutic responsiveness to different adjuvant chemotherapeutic regimens. They would also better inform and more appropriately power clinical trials because approximately 40% of patients have a histomolecular intestinal phenotype carcinoma with no lymph node involvement, and any benefit would likely not be

detectable. To study a disease with such a broad range of outcomes in a clinical trial setting would require large numbers if specific patient subgroups were not enriched. Adenocarcinomas of the ampulla of Vater are a clear example where trials targeting a specific phenotypic subgroup would be most appropriate. These targeted trials would require smaller numbers to detect a larger effect, improving feasibility and decreasing cost.³³

In conclusion, a combination of histopathologic and molecular criteria defines distinct clinically and biologically relevant histomolecular phenotypes of adenocarcinoma of the ampulla of Vater, with different outcomes and potentially different chemosensitivity profiles. Prospective assessment of this approach is encouraged to define its utility in clinical practice.

AUTHORS' DISCLOSURES OF POTENTIAL CONFLICTS OF INTEREST

Although all authors completed the disclosure declaration, the following author(s) and/or an author's immediate family member(s) indicated a financial or other interest that is relevant to the subject matter under consideration in this article. Certain relationships marked with a "U" are those for which no compensation was received; those relationships marked with a "C" were compensated. For a detailed description of the disclosure categories, or for more information about ASCO's conflict of interest policy, please refer to the Author Disclosure Declaration and the Disclosures of Potential Conflicts of Interest section in Information for Contributors.

Employment or Leadership Position: None **Consultant or Advisory Role:** Anthony J. Gill, Cook Medical (C) **Stock Ownership:** None **Honoraria:** None **Research Funding:** None **Expert Testimony:** None **Other Remuneration:** None

REFERENCES

- Howe JR, Klimstra DS, Moccia RD, et al: Factors predictive of survival in ampullary carcinoma. *Ann Surg* 228:87-94, 1998
- Roder JD, Schneider PM, Stein HJ, et al: Number of lymph node metastases is significantly associated with survival in patients with radically resected carcinoma of the ampulla of Vater. *Br J Surg* 82:1693-1696, 1995
- Yeo CJ, Sohn TA, Cameron JL, et al: Periampullary adenocarcinoma: Analysis of 5-year survivors. *Ann Surg* 227:821-831, 1998
- Bouvet M, Gamagami RA, Gilpin EA, et al: Factors influencing survival after resection for periampullary neoplasms. *Am J Surg* 180:13-17, 2000
- O'Connell JB, Maggard MA, Manunga J Jr, et al: Survival after resection of ampullary carcinoma: A national population-based study. *Ann Surg Oncol* 15:1820-1827, 2008
- Albores-Saavedra J, Schwartz AM, Batich K, et al: Cancers of the ampulla of Vater: Demographics, morphology, and survival based on 5,625 cases from the SEER program. *J Surg Oncol* 100:598-605, 2009
- Hatzaras I, George N, Muscarella P, et al: Predictors of survival in periampullary cancers following pancreaticoduodenectomy. *Ann Surg Oncol* 17:991-997, 2010
- Winter JM, Cameron JL, Olino K, et al: Clinicopathologic analysis of ampullary neoplasms in 450 patients: Implications for surgical strategy and long-

term prognosis. *J Gastrointest Surg* 14:379-387, 2010

9. Klinkenbijl JH, Jeekel J, Sahnoud T, et al: Adjuvant radiotherapy and 5-fluorouracil after curative resection of cancer of the pancreas and periampullary region: Phase III trial of the EORTC gastrointestinal tract cancer cooperative group. *Ann Surg* 230:776-782, 1999; discussion 782-784

10. Takada T, Amano H, Yasuda H, et al: Is postoperative adjuvant chemotherapy useful for gallbladder carcinoma? A phase III multicenter prospective randomized controlled trial in patients with resected pancreaticobiliary carcinoma. *Cancer* 95:1685-1695, 2002

11. Smeenk HG, van Eijck CH, Hop WC, et al: Long-term survival and metastatic pattern of pancreatic and periampullary cancer after adjuvant chemoradiation or observation: Long-term results of EORTC trial 40891. *Ann Surg* 246:734-740, 2007

12. Lee JH, Whittington R, Williams NN, et al: Outcome of pancreaticoduodenectomy and impact of adjuvant therapy for ampullary carcinomas. *Int J Radiat Oncol Biol Phys* 47:945-953, 2000

13. Mehta VK, Fisher GA, Ford JM, et al: Adjuvant chemoradiotherapy for "unfavorable" carcinoma of the ampulla of Vater: Preliminary report. *Arch Surg* 136:65-69, 2001

14. Sikora SS, Balachandran P, Dimri K, et al: Adjuvant chemo-radiotherapy in ampullary cancers. *Eur J Surg Oncol* 31:158-163, 2005

15. Bhatia S, Miller RC, Haddock MG, et al: Adjuvant therapy for ampullary carcinomas: The Mayo

AUTHOR CONTRIBUTIONS

Conception and design: David K. Chang, Nigel B. Jamieson, Amber L. Johns, Christopher J. Scarlett, Marina Pajic, Angela Chou, Jeremy L. Humphris, Marc D. Jones, Adnan M. Nagrial, Lorraine A. Chantrill, Ilse Rooman, Jaswinder S. Samra, Rita T. Lawlor, Samantha Bersani, Euan J. Dickson, Mohamed A.A. Mohamed, Robert L. Sutherland, James G. Kench, C. Ross Carter, Anthony J. Gill, Aldo Scarpa, Colin J. McKay, Andrew V. Biankin

Financial support: Robert L. Sutherland, Aldo Scarpa, Andrew V. Biankin

Administrative support: Robert L. Sutherland, Andrew V. Biankin

Provision of study materials or patients: David K. Chang, Nigel B. Jamieson, Jaswinder S. Samra, Claudio Bassi, Massimo Falconi, Euan J. Dickson, Karin A. Oien, C. Ross Carter, Aldo Scarpa, Colin J. McKay, Andrew V. Biankin

Collection and assembly of data: David K. Chang, Nigel B. Jamieson, Amber L. Johns, Christopher J. Scarlett, Marina Pajic, Angela Chou, Jeremy L. Humphris, Christopher Toon, Emily K. Colvin, Jaswinder S. Samra, Vincenzo Corbo, Claudio Bassi, Massimo Falconi, Rita T. Lawlor, Nicola Sperandio, Samantha Bersani, Mohamed A.A. Mohamed, Karin A. Oien, Alan K. Foulis, Anthony J. Gill, Aldo Scarpa, Colin J. McKay, Andrew V. Biankin

Data analysis and interpretation: David K. Chang, Nigel B. Jamieson, Amber L. Johns, Christopher J. Scarlett, Marina Pajic, Angela Chou, Mark Pinese, Jeremy L. Humphris, Marc D. Jones, Adnan M. Nagrial, Lorraine A. Chantrill, Venessa T. Chin, Andreia V. Pinho, Ilse Rooman, Mark J. Cowley, Jianmin Wu, R. Scott Mead, Jaswinder S. Samra, Massimo Falconi, Rita T. Lawlor, Stefano Crippa, Samantha Bersani, Euan J. Dickson, Mohamed A.A. Mohamed, Karin A. Oien, Elizabeth A. Musgrove, Robert L. Sutherland, James G. Kench, C. Ross Carter, Anthony J. Gill, Aldo Scarpa, Colin J. McKay, Andrew V. Biankin

Manuscript writing: All authors

Final approval of manuscript: All authors

Clinic experience. *Int J Radiat Oncol Biol Phys* 66:514-519, 2006

16. Krishnan S, Rana V, Evans DB, et al: Role of adjuvant chemoradiation therapy in adenocarcinomas of the ampulla of Vater. *Int J Radiat Oncol Biol Phys* 70:735-743, 2008

17. Zhou J, Hsu CC, Winter JM, et al: Adjuvant chemoradiation versus surgery alone for adenocarcinoma of the ampulla of Vater. *Radiother Oncol* 92:244-248, 2009

18. Kim K, Chie EK, Jang JY, et al: Role of adjuvant chemoradiotherapy for ampulla of Vater cancer. *Int J Radiat Oncol Biol Phys* 75:436-441, 2009

19. Westgaard A, Tafford S, Farstad IN, et al: Pancreatobiliary versus intestinal histologic type of differentiation is an independent prognostic factor in resected periampullary adenocarcinoma. *BMC Cancer* 8:170, 2008

20. Carter JT, Grenert JP, Rubenstein L, et al: Tumors of the ampulla of Vater: Histopathologic classification and predictors of survival. *J Am Coll Surg* 207:210-218, 2008

21. Hansel DE, Maitra A, Lin JW, et al: Expression of the caudal-type homeodomain transcription factors CDX 1/2 and outcome in carcinomas of the ampulla of Vater. *J Clin Oncol* 23:1811-1818, 2005

22. Chu PG, Schwarz RE, Lau SK, et al: Immunohistochemical staining in the diagnosis of pancreatobiliary and ampulla of Vater adenocarcinoma: Application of CDX2, CK17, MUC1, and MUC2. *Am J Surg Pathol* 29:359-367, 2005

23. Zhou H, Schaefer N, Wolff M, et al: Carcinoma of the ampulla of Vater: Comparative histologic/

immunohistochemical classification and follow-up. *Am J Surg Pathol* 28:875-882, 2004

24. Mani S, Kugler J, Knost J, et al: Phase II trial of 150-minute weekly infusion of gemcitabine in advanced colorectal cancer: Minimal activity in colorectal cancer. *Invest New Drugs* 16:275-278, 1998-1999
25. Neoptolemos JP, Moore MJ, Cox TF, et al: Effect of adjuvant chemotherapy with fluorouracil plus folinic acid or gemcitabine vs observation on survival in patients with resected periampullary adenocarcinoma: The ESPAC-3 periampullary cancer randomized trial. *JAMA* 308:147-156, 2012
26. Edge SB, Byrd DR, Carducci M (eds): *AJCC Cancer Staging Manual*. New York, NY, Springer, 2009
27. Chu P, Wu E, Weiss LM: Cytokeratin 7 and cytokeratin 20 expression in epithelial neoplasms: A survey of 435 cases. *Mod Pathol* 13:962-972, 2000
28. Lau SK, Weiss LM, Chu PG: Differential expression of MUC1, MUC2, and MUC5AC in carcinomas of various sites: An immunohistochemical study. *Am J Clin Pathol* 122:61-69, 2004
29. Werling RW, Yaziji H, Bacchi CE, et al: CDX2, a highly sensitive and specific marker of adenocarcinomas of intestinal origin: An immunohistochemical survey of 476 primary and metastatic carcinomas. *Am J Surg Pathol* 27:303-310, 2003
30. Moskaluk CA, Zhang H, Powell SM, et al: Cdx2 protein expression in normal and malignant human tissues: An immunohistochemical survey using tissue microarrays. *Mod Pathol* 16:913-919, 2003
31. Yonezawa S, Higashi M, Yamada N, et al: Significance of mucin expression in pancreaticobiliary neoplasms. *J Hepatobiliary Pancreat Sci* 17:108-124, 2010
32. McShane LM, Altman DG, Sauerbrei W, et al: Reporting recommendations for tumor marker prognostic studies. *J Clin Oncol* 23:9067-9072, 2005
33. LoRusso PM, Schnipper LE, Stewart DJ, et al: Translating clinical trials into meaningful outcomes. *Clin Cancer Res* 16:5951-5955, 2010

Affiliations

David K. Chang, Amber L. Johns, Christopher J. Scarlett, Marina Pajic, Angela Chou, Mark Pinese, Jeremy L. Humphris, Marc D. Jones, Christopher Toon, Adnan M. Nagrial, Lorraine A. Chantrill, Venessa T. Chin, Andreia V. Pinho, Ilse Rooman, Mark J. Cowley, Jianmin Wu, R. Scott Mead, Emily K. Colvin, Elizabeth A. Musgrove, Robert L. Sutherland, James G. Kench, Anthony J. Gill, and Andrew V. Biankin, Kinghorn Cancer Centre and Garvan Institute of Medical Research; David K. Chang and Andrew V. Biankin, Bankstown Hospital; David K. Chang and Andrew V. Biankin, University of New South Wales; Angela Chou, St Vincent's Hospital; Jaswinder S. Samra and Anthony J. Gill, Royal North Shore Hospital; Jaswinder S. Samra, James G. Kench, and Anthony J. Gill, Sydney Medical School, University of Sydney; James G. Kench, Royal Prince Alfred Hospital, Sydney; Christopher J. Scarlett, University of Newcastle, Ourimbah; Lorraine A. Chantrill, Macarthur Cancer Therapy Centre, Campbelltown, New South Wales, Australia; Nigel B. Jamieson, Euan J. Dickson, C. Ross Carter, and Colin J. McKay, Glasgow Royal Infirmary; Nigel B. Jamieson, Mohamed A.A. Mohamed, Karin A. Oien, and Alan K. Foulis, University of Glasgow; Karin A. Oien and Alan K. Foulis, Southern General Hospital, Glasgow, United Kingdom; and Vincenzo Corbo, Claudio Bassi, Massimo Falconi, Rita T. Lawlor, Stefano Crippa, Nicola Sperandio, Samantha Bersani, and Aldo Scarpa, University of Verona, Verona, Italy.

